



# Acute scrotal pain in adults

**Author:** Robert C Eyre, MD

**Section Editor:** Michael P O'Leary, MD, MPH

**Deputy Editor:** Jane Givens, MD

All topics are updated as new evidence becomes available and our [peer review process](#) is complete.

**Literature review current through:** Jun 2021. | **This topic last updated:** Jun 28, 2021.

## INTRODUCTION

The spectrum of conditions affecting the scrotum and its contents ranges from acute pathologic events that require immediate surgical intervention to incidental findings that simply require patient reassurance.

This topic addresses the clinical evaluation and management of the acute scrotum, which is defined as moderate to severe scrotal pain that develops over the course of minutes to one to two days, in adults. Nonacute scrotal conditions in adults and scrotal disorders in children and adolescents are discussed separately. (See "[Nonacute scrotal conditions in adults](#)" and "[Evaluation of nontraumatic scrotal pain or swelling in children and adolescents](#)".)

## NORMAL ANATOMY

The testis, tunica vaginalis, epididymis, spermatic cord, appendix testis, and appendix epididymis are anatomic structures that may be involved in scrotal conditions ( [figure 1](#)):

- The testis (testicle) is the male gonad responsible for production of sperm and androgens (primarily testosterone). The normal testis is ovoid, about 3 to 5 cm in length, and firm with smooth surfaces. One testis may be slightly larger than the other, and one testis (usually the left) may hang slightly lower.
- The tunica vaginalis is a fascial layer which encapsulates a potential space that encompasses the anterior two-thirds of the testis. Different types of fluid may accumulate within the tunica vaginalis (eg, serum with a hydrocele, blood with a hematocele, pus with a pyocele).

- The epididymis is a tightly coiled tubular structure located on the posterior aspect of the testis running from its superior to inferior poles. Sperm travels from the tubules of the rete testis into the epididymis, which joins the vas deferens distally. The function of the epididymis is to aid in the storage and transport of sperm cells that are produced in the testes, as well as to facilitate sperm maturation.
- The spermatic cord, which consists of the testicular blood vessels and the vas deferens, is connected to the base of the epididymis and traverses into the retropubic space.
- The appendix testis is a small vestigial structure on the anterosuperior aspect of the testis, representing an embryologic remnant of the Müllerian duct system ( [figure 2](#)). It measures approximately 0.3 cm in length and is predisposed to torsion (twisting), particularly during childhood, because of its pedunculated shape. The appendix epididymis is a Wolffian duct vestigial structure found on the top of the epididymis.

---

## PATIENT EVALUATION

**Conditions requiring emergent treatment** — The first priority in the evaluation of the acute scrotum is to identify conditions that require urgent medical or surgical intervention, namely testicular torsion, acute epididymitis (or epididymo-orchitis), and Fournier's gangrene. These diagnoses are all associated with diffuse scrotal pain.

Delayed diagnosis and treatment of acute epididymitis is associated with increased morbidity. Delayed surgical intervention of testicular torsion can lead to loss of the testis, infertility, and other complications.

Testicular torsion and acute epididymitis are the most common causes of acute scrotal pain in adults. Although much less common, Fournier's gangrene (necrotizing fasciitis of the perineum), which can cause acute scrotal swelling, is a surgical emergency. (See '[Acute epididymitis or epididymo-orchitis](#)' below and '[Testicular torsion](#)' below and '[Fournier's gangrene](#)' below.)

**Initial evaluation** — The initial evaluation of acute scrotal pain includes a directed history and physical examination including vital signs.

Patients should be asked about the nature and timing of the onset of pain, its location, and the presence of fever and lower urinary tract symptoms (eg, frequency, urgency, dysuria). Patients should be asked about any prior history of inguinal or scrotal surgery.

The abdomen, inguinal region, and scrotal skin and contents should be carefully examined ( [figure 1](#)). The normal testis is ovoid, about 3 to 5 cm in length, and firm with smooth surfaces. One testis may be slightly larger than the other, and one testis (usually the left)

may hang slightly lower. The epididymis, which is a spongy, tube-shaped structure, is palpable along the posterior aspect of each testis.

The cremasteric reflex (lightly stroking the superior and medial part of the thigh to make the cremaster muscle contract and pull up the ipsilateral testis) should be assessed. A negative cremasteric reflex is associated with testicular torsion.

Examination for an inguinal hernia is best performed with the patient standing. The inguinal areas should be inspected for bulges, and a provocative maneuver (eg, cough) may be necessary to expose the hernia. If a hernia is not apparent on inspection, the maneuver should be repeated as the clinician invaginates the upper scrotum. (See "[Classification, clinical features, and diagnosis of inguinal and femoral hernias in adults](#)", section on '[Diagnosis](#)'.)

The location and characteristics of scrotal symptoms and physical examination findings can inform the probable cause, as outlined below ( [table 1](#)). For example, the onset of testicular torsion may be acute and severe, while epididymitis typically has a more gradual onset.

## Diagnostic considerations

**Diffuse scrotal pain** — The main diagnostic considerations for diffuse scrotal pain include testicular torsion, acute epididymo-orchitis, and Fournier's gangrene.

In patients with fever, tachycardia, or hypotension, Fournier's gangrene (ie, necrotizing fasciitis of the perineum) should be considered. Typical symptoms include diffuse scrotal, groin, and lower abdominal pain, tenderness, and swelling ( [picture 1](#)). Other clinical signs may include tense edema outside the involved skin, blisters/bullae, crepitus, and subcutaneous gas. This diagnosis necessitates urgent surgical evaluation. (See '[Fournier's gangrene](#)' below.)

If Fournier's gangrene is not suspected, testing the cremasteric reflex may be helpful in determining the most likely cause of diffuse scrotal pain [[1](#)].

- If the cremasteric reflex is negative (the testis does not pull up when the ipsilateral thigh is stroked), a presumptive diagnosis of testicular torsion should be suspected. The cremasteric reflex is most often seen in boys between 30 months and 12 years of age, and it is less consistent in older males; thus, no singular test should be used to establish a diagnosis of torsion. Other supportive findings include a high-riding testis, bell clapper deformity ( [figure 3](#)), and profound testicular swelling. If clinical features are classic, the diagnosis can be made on these findings alone. However, if the findings are less clear, scrotal ultrasound should be performed to confirm the diagnosis. All patients with

suspected or confirmed testicular torsion should be referred urgently for urologic evaluation. (See ['Testicular torsion'](#) below.)

- If the cremasteric reflex is positive (the testis pulls up when the ipsilateral thigh is stroked), acute epididymo-orchitis or orchitis is a more likely diagnosis.
  - In acute epididymo-orchitis, there is pain, swelling, and tenderness of the testis with some localization posteriorly. Epididymal swelling and pain typically precede secondary inflammatory changes in the testis. Fever and lower urinary tract symptoms may be present. Urinalysis, urine culture, and urine studies for *Neisseria gonorrhoeae* and *Chlamydia trachomatis* should be obtained in this setting. For patients with suspected acute epididymo-orchitis, antibiotic therapy should be given empirically while awaiting test results. (See ['Acute epididymitis or epididymo-orchitis'](#) below.)
  - Acute orchitis from mumps is characterized by diffuse testicular swelling and tenderness and may be difficult to distinguish from acute epididymo-orchitis. Supportive findings for mumps would include a local outbreak and the presence of constitutional symptoms and parotitis. Suspicion of mumps should prompt serologic testing. (See ['Other etiologies'](#) below.)

**Localized scrotal pain** — For patients with localized scrotal pain and tenderness, the location can suggest potential causes.

- If symptoms are localized to the posterior aspect of the testis, a presumptive diagnosis of acute epididymitis can be made. Lower urinary tract symptoms may be present. Urinalysis, urine culture, and urine studies for *N. gonorrhoeae* and *C. trachomatis* should be obtained in this setting. For patients with suspected acute epididymitis, antibiotic therapy should be given empirically while awaiting test results. (See ['Acute epididymitis or epididymo-orchitis'](#) below.)
- If symptoms are localized to the anterior superior pole of the testis, testicular appendiceal torsion is likely. Another supportive finding is the blue dot sign ( [picture 2](#) ), which occurs in a minority of patients. (See ['Other etiologies'](#) below.)

**Additional evaluation** — When the cause of scrotal pain is not evident after the initial evaluation, or symptoms do not improve with empiric treatment, other causes of scrotal pain should be considered. These include trauma, post-vasectomy pain, testicular cancer, immunoglobulin A (IgA) vasculitis (Henoch-Schönlein purpura), acute idiopathic scrotal edema, and referred pain (diagnosis of exclusion). In these settings, a scrotal ultrasound and urology referral for consultation are advised. (See ['Other etiologies'](#) below.)

## ACUTE EPIDIDYMITIS OR EPIDIDYMO-ORCHITIS

Acute epididymitis is the most common cause of scrotal pain in adults in the outpatient setting, accounting for 600,000 cases per year in the United States [2]. More advanced cases may present with testicular pain, swelling, and tenderness (epididymo-orchitis). As the evaluation and management of acute epididymo-orchitis is similar to that of acute epididymitis [3], we will refer only to acute epididymitis in this section.

**Etiology** — Acute epididymitis is most commonly infectious in etiology but can also be from noninfectious causes such as trauma and autoimmune diseases [4]. Noninfectious causes generally present as subacute or chronic epididymitis and are discussed elsewhere. (See ["Nonacute scrotal conditions in adults", section on 'Chronic epididymitis'.](#))

*N. gonorrhoeae* and *C. trachomatis* are the most common organisms responsible for acute epididymitis in men under the age of 35 [4-6]. (See ["Clinical manifestations and diagnosis of \*Neisseria gonorrhoeae\* infection in adults and adolescents"](#) and ["Clinical manifestations and diagnosis of \*Chlamydia trachomatis\* infections", section on 'Clinical syndromes in males'.](#))

*Escherichia coli*, other coliforms, and *Pseudomonas* species are more frequent in older men, often in association with obstructive uropathy from benign prostatic hyperplasia. Men of any age who engage in insertive anal intercourse are also at increased risk for acute bacterial epididymitis from exposure to coliform bacteria in the rectum. Other less common organisms responsible for acute epididymitis include *Ureaplasma* species, *Mycoplasma genitalium* (see ["Mycoplasma genitalium infection in men and women"](#)), *Mycobacterium tuberculosis*, and *Brucella* species.

**Clinical features and diagnosis** — The clinical features of acute epididymitis include localized testicular pain with tenderness and swelling on palpation of the affected epididymis, which is located posteriorly on the testis ( [figure 1](#)). More advanced cases present with secondary testicular pain and swelling (epididymo-orchitis). Scrotal wall erythema and a reactive hydrocele may be present. A positive Prehn sign (manual elevation of the scrotum relieves pain) is more often seen with epididymitis than testicular torsion. The cremasteric reflex is positive.

In rare cases, acute epididymitis can cause serious illness. It is characterized by severe pain and swelling of the surrounding structures, often accompanied by fever, rigors, and lower urinary tract symptoms (frequency, urgency, and dysuria). It may be seen in conjunction with acute prostatitis (epididymo-prostatitis), particularly in older men who may have underlying prostatic obstruction or have undergone recent urologic instrumentation or catheterization.

The diagnosis of acute epididymitis is made presumptively based on history and physical examination after ruling out other causes requiring urgent surgical intervention (see

['Conditions requiring emergent treatment'](#) above). In all suspected cases, a urinalysis, urine culture, and a urine nucleic acid amplification test (NAAT) for *N. gonorrhoeae* and *C. trachomatis* should be performed, although urinalysis and urine culture are often negative in patients without lower urinary tract symptoms [7]. Identification of a pathogen on urine or urethral swab testing supports the presumptive diagnosis.

With the exception of mumps, isolated orchitis without epididymitis is very uncommon in adults and so epididymo-orchitis should be the primary diagnosis to consider when an adult appears to have orchitis. However, in non-immune adults, mumps and other "childhood" viruses can rarely cause orchitis. (See ["Causes of scrotal pain in children and adolescents"](#), [section on 'Orchitis'](#) and ['Other etiologies'](#) below.)

**Management** — Management of acute epididymitis varies according to its severity [2]. Most cases can be treated on an outpatient basis with oral antibiotics, nonsteroidal antiinflammatory drugs (NSAIDs), local application of ice, and scrotal elevation.

Acutely ill patients may warrant hospitalization for parenteral antibiotics and intravenous hydration. Urine cultures should be done to identify a possible causative organism, along with initiation of empiric antibiotics. For patients younger than 35 years old, [ceftriaxone](#) 1 to 2 g every 24 hours depending on the clinical severity (or in equally divided doses every 12 hours), and for older patients a fluoroquinolone such as [ciprofloxacin](#) 400 mg every 12 hours, would be appropriate. The duration of intravenous therapy would usually be for a minimum of two to four days or until afebrile for 24 hours, with a switch to oral therapy based upon sensitivity data from a urine culture. If a scrotal abscess is clinically suspected or a patient fails to improve on therapy after 48 hours, an ultrasound should be obtained. The total duration of antibiotic therapy should be 10 to 14 days.

Outpatient empiric antimicrobial treatment should be given pending NAAT and culture results based on the most likely pathogens as follows:

- **Patients under the age of 35 or who are at risk of sexually transmitted infections** (eg, sex outside of monogamous relationship) – We suggest coverage for *N. gonorrhoeae* and *C. trachomatis* with [ceftriaxone](#) (500 mg intramuscular injection in one dose, or 1 g if patient weighs 150 kg or greater) plus [doxycycline](#) (100 mg orally twice a day for 10 days) [8]. For patients unable to tolerate doxycycline, a single [azithromycin](#) dose (1 g orally) is an alternative option. For patients unable to tolerate ceftriaxone due to cephalosporin allergy, a single 240 mg intramuscular dose of [gentamicin](#) plus a single 2 g oral dose of azithromycin is an option.

Fluoroquinolones are not recommended for the treatment of acute epididymitis if gonorrhea is suspected because of the widespread resistance of *N. gonorrhoeae* to these

drugs. (See "[Treatment of uncomplicated \*Neisseria gonorrhoeae\* infections](#)", section on '[Fluoroquinolones](#)'.)

- **Patients 35 years of age or older and who are at low risk for sexually transmitted infections** – We suggest coverage for enteric pathogens with [levofloxacin](#) 500 mg orally once daily for 10 days. For patients who are unable to take fluoroquinolones, [trimethoprim-sulfamethoxazole](#) (one double-strength tablet twice a day for 10 days) is a good alternative.
- **Patients of any age who practice insertive anal intercourse** – We suggest coverage for *N. gonorrhoeae*, *C. trachomatis*, and enteric pathogen infections with [ceftriaxone](#) (500 mg intramuscular injection in one dose, or 1 g if patient weighs 150 kg or greater) **plus** a fluoroquinolone ([levofloxacin](#) 500 mg orally once daily for 10 days).

These treatment regimens are in accordance with the US Centers for Disease Control and Prevention (CDC) guidelines [8]. Studies defining the optimal antimicrobial regimens for acute epididymitis are limited, and the selection of drugs is based on treatment evidence for other types of infections with these pathogens. In general, [doxycycline](#) is preferred over [azithromycin](#) for the management of chlamydial epididymitis because of the lack of studies on the latter drug for this infection. (See "[Treatment of uncomplicated \*Neisseria gonorrhoeae\* infections](#)" and "[Treatment of \*Chlamydia trachomatis\* infection](#)".)

Patients with acute epididymitis should generally improve within 48 to 72 hours after starting appropriate antibiotic therapy. If the symptoms are not better, other causes of scrotal pain should be considered. Scrotal ultrasound and referral to a urologist for consultation are advised.

Patients who are diagnosed with *N. gonorrhoeae* or *C. trachomatis* epididymitis should be retested in several months because of the high rate of reinfection and should be instructed to refer their sexual partners for evaluation and treatment. (See "[Treatment of uncomplicated \*Neisseria gonorrhoeae\* infections](#)", section on '[Management of sexual partners](#)' and "[Treatment of \*Chlamydia trachomatis\* infection](#)", section on '[Management of sex partners](#)'.)

---

## TESTICULAR TORSION

**Epidemiology** — Testicular torsion is a urologic emergency that is more common in neonates and postpubertal boys than adults, although it can occur at any age [9]. In one retrospective review, 17 of 44 cases (39 percent) of testicular torsion in hospitalized patients were in men ages 21 and older [10]. The prevalence of testicular torsion in adult patients hospitalized with acute scrotal pain is 25 to 50 percent [9,11-14]. Testicular torsion in children

is discussed separately. (See ["Causes of scrotal pain in children and adolescents", section on 'Testicular torsion'](#).)

**Pathophysiology** — Testicular torsion results from inadequate fixation of the lower pole of the testis to the tunica vaginalis ( [figure 1](#)). If fixation is absent or insufficiently broad-based, the testis may torse (twist) on the spermatic cord, potentially producing ischemia from reduced arterial inflow and venous outflow obstruction ( [figure 4](#)). Testicular torsion may occur after an inciting event (eg, trauma, vigorous physical activity) or spontaneously.

It is generally believed that the testis suffers irreversible damage after eight hours of ischemia from testicular torsion [[7,15](#)]. Infertility may result, even with a normal contralateral testis. This may be due to disruption of the immunologic "blood-testis" barrier, and exposure of antigens from germ cells and sperm to the general circulation, with subsequent development of anti-sperm antibodies [[16](#)]. However, a more likely cause is loss of overall germ cell volume [[17](#)].

**Clinical features and diagnosis** — The clinical features of testicular torsion include the acute onset of moderate to severe testicular pain with profound diffuse tenderness and swelling and a negative cremasteric reflex on physical examination.

Symptoms often occur several hours after vigorous physical activity or minor trauma to the testicles [[18](#)]. Nausea and vomiting as well as diffuse lower abdominal pain may be associated. Patients may present initially with lower abdominal pain, nausea, and vomiting without localization of pain to the scrotum. Thus, all patients with these symptoms should have a thorough scrotal examination. Another common presentation, particularly in children, is awakening with scrotal pain in the middle of the night or in the morning, likely related to cremasteric contraction with nocturnal sexual stimulation during the rapid eye movement sleep cycle. The patient should be asked about prior similar episodes that might suggest intermittent testicular torsion.

The classic finding is an asymmetrically high-riding testis with its long axis oriented transversely instead of longitudinally related to shortening of the spermatic cord from the torsion ("bell clapper deformity") ( [figure 3](#)). Profound testicular swelling occurs early, while a reactive hydrocele and overlying erythema of the scrotal wall may be evident 12 to 24 hours after the onset of symptoms. In the early stages, an experienced examiner can often differentiate the swollen, exquisitely tender testis from the softer, less tender epididymis posteriorly. The finding of a tender mass ("knot") superior to the testis makes the diagnosis of torsion extraordinarily likely. It is often possible to detorse a testis during examination by gentle rotation away from the midline. Relief of pain with detorsion indicates likely testicular torsion. (See ['Manual detorsion'](#) below.)



The cremasteric reflex should be assessed, and is usually absent in patients with testicular torsion ( [table 1](#)). This finding helps distinguish testicular torsion from acute epididymitis or epididymo-orchitis and other causes of scrotal pain in which the reflex is generally intact [1]. The cremasteric reflex is assessed by stroking or gently pinching the skin of the upper thigh while observing the ipsilateral testis. A normal response is cremasteric contraction with elevation of the testis (see '[Diffuse scrotal pain](#)' above). The cremasteric reflex is most often seen in boys between 30 months and 12 years of age, and it is less consistent in older males; thus, no singular test should be used to establish a diagnosis of torsion.

Patients clinically suspected of having testicular torsion should be immediately referred to a urologist or emergency department for evaluation.

**Ultrasound** — Many cases of testicular torsion do not require imaging to confirm the diagnosis if the history and physical examination are pathognomonic. However, in equivocal cases, color Doppler ultrasonography should be urgently obtained. It is important to request that the ultrasonographer perform a thorough evaluation of the spermatic cord up to the level of the internal ring, and not just limit the examination to the scrotum. However, if access to scrotal ultrasonography is unavailable or if the ultrasound cannot exclude testicular torsion, surgical exploration is advised [19].

It is also important to note that scrotal ultrasounds may occasionally show present but diminished blood flow to the testis and epididymis or even increased blood flow to the epididymis as the result of reperfusion if a testis has either spontaneously or manually detorsed. Therefore, the importance of a careful history and physical examination as well as a clear understanding of the possible limitations in interpreting imaging studies cannot be overstated.

In a study of 56 patients who underwent surgical exploration for acute scrotal pain and had an ultrasound performed preoperatively [11], none of the 22 patients with testicular torsion at surgical exploration had a detectable Doppler signal over the affected side (sensitivity 100 percent). By contrast, normal testicular blood flow and cord-compression tests were demonstrated clearly in 33 of 34 patients who did not have testicular torsion (specificity 97 percent). In another report, ultrasonography had a sensitivity and specificity of 82 and 100 percent, respectively, for the diagnosis of testicular torsion [20]. Subsequent studies confirmed the high sensitivity and specificity of ultrasound in the diagnosis of testicular torsion, although results may vary based on ultrasound technique [21,22].

Utilization of high-resolution ultrasonography has further increased the sensitivity and specificity of diagnosing testicular torsion. In this technique, the twisting of the spermatic cord is directly visualized as an inhomogeneous mass at the inguinal or paratesticular position (the "Whirlpool Sign") [23,24]. In a study of 919 patients (mean age 9 years; range 1 day to 19 years), traditional color Doppler ultrasonography of the scrotum had a sensitivity

of 76 percent, while high-resolution ultrasonography of the spermatic cord for linear or twist configuration reached 96 and 99 percent sensitivity and specificity, respectively [25].

**Management** — Treatment for suspected testicular torsion is urgent surgical exploration with intraoperative detorsion and fixation of the testes. Delay in detorsion of a few hours may lead to progressively higher rates of testicular nonviability. Manual detorsion should be performed if surgical intervention is not immediately available.

**Surgery** — Detorsion and fixation of both the involved testis and the contralateral uninvolved testis should be performed since inadequate gubernacular fixation is usually a bilateral defect. Extended periods of ischemia (>8 hours) may cause infarction of the testis with necrosis requiring orchiectomy. Further testicular ischemic injury may occur even after detorsion due to a “testicular compartment syndrome.” This occurs when reperfusion and parenchymal edema in the space confined by the inelastic tunica albuginea cause increased pressure, which may reduce parenchymal blood flow. In a case report of three patients, all of whom had ischemia for at least six hours, an incision in the tunica albuginea and placement of a tunica vaginalis patch after reduction of the torsion resulted in salvage of the testis in all patients with preservation of size and symmetrical growth at one-year follow-up [26].

The outcome of surgery may be worse in adults than in children. In one retrospective study, the testicular salvage rates of patients age <21 years and age ≥21 years were 70 and 41 percent, respectively [10]. While the time to presentation was the most important factor affecting the salvage rate, adult men also had a greater degree of cord twisting than the younger group, which may partly explain the difference in outcomes.

Color Doppler ultrasonography has been used to predict the outcome of testicular salvage. In one study, the paired findings of no blood flow to the testis and heterogeneous echotexture of the testicular parenchyma were 100 percent predictive of testicular loss at exploration [27]. However, one should be very cautious about delaying urgent surgery even in the presence of these findings if there is any clinical judgment that that testis may still be salvageable.

**Manual detorsion** — If surgery is not available within two hours, an attempt to detorse the testicle manually is warranted ( [figure 5](#)). Observational studies in children have suggested relief of pain and improved testicular salvage with manual detorsion (see "[Causes of scrotal pain in children and adolescents](#)", [section on 'Manual detorsion'](#)). In general, analgesics are not given because of concern of masking continued torsion. Surgical exploration is necessary even after successful manual detorsion because orchiopexy (securing the testicle to the scrotal wall) should be performed to prevent recurrence, and residual torsion may be present that can be further relieved [28].

The classic teaching is that the testis usually rotates medially during torsion and can be detorsed by rotating it outward toward the thigh. However, in a retrospective analysis of 200 consecutive males age 18 months to 20 years who underwent surgical exploration for testicular torsion, lateral rotation was present in one-third of cases [28]. The degree of twisting of the testis may range from 180 to 720 degrees, requiring multiple rounds of detorsion.

Successful detorsion is suggested by [29]:

- Relief of pain
- Conversion of the transverse lie of the testis to a longitudinal orientation
- Lower position of the testis in the scrotum
- Return of normal arterial pulsations on color Doppler ultrasound

---

## FOURNIER'S GANGRENE

Fournier's gangrene is a necrotizing fasciitis (mixed aerobic/anaerobic infection) of the perineum which often involves the scrotum (see "[Necrotizing soft tissue infections](#)"). It is typically seen in patients who are diabetic, have had longstanding indwelling urethral catheters, have had urethral trauma in the presence of urinary infection, or are immunocompromised.

It is characterized by severe pain that generally starts on the anterior abdominal wall and migrates into the gluteal muscles, scrotum, and penis ( [picture 1](#)). Clinical features may include tense edema outside the involved skin, blisters/bullae, crepitus, and subcutaneous gas, as well as systemic findings such as fever, tachycardia, and hypotension. Computed tomography (CT) and magnetic resonance imaging (MRI) may show air along the fascial planes or deeper tissue involvement. However, imaging studies should not delay surgical exploration when there is clinical evidence of progressive soft tissue infection. (See "[Necrotizing soft tissue infections](#)", [section on 'Clinical manifestations'](#).)

Treatment of necrotizing fasciitis consists of early aggressive surgical exploration with debridement of necrotic tissue, broad spectrum antibiotic therapy, and hemodynamic support as needed [30]. Patients with Fournier's gangrene may ultimately require cystostomy, colostomy, or orchiectomy. (See "[Necrotizing soft tissue infections](#)", [section on 'Treatment'](#) and "[Surgical management of necrotizing soft tissue infections](#)".)

---

## OTHER ETIOLOGIES

- **Torsion of the appendix testis** – Torsion of the appendix testis rarely occurs in adults [31]. Most cases are in children between the ages of 7 and 14 years, with a mean age of

10.6 years [32]. (See "[Causes of scrotal pain in children and adolescents](#)", section on "[Torsion of the appendix testis or appendix epididymis](#)".)

The onset of testicular pain from torsion of the appendix testis is generally more gradual than with testicular torsion and may range from mild to severe. On physical examination, a reactive hydrocele is often present that may transilluminate, and tenderness is localized to the appendix testis on the anterosuperior testis. Careful inspection of the scrotal wall may detect the classic "blue dot" sign ( [picture 2](#)), which is caused by infarction and necrosis of the appendix testis but seen in a minority of patients [33,34].

If the diagnosis is unclear on physical examination, a scrotal ultrasound can be performed that will show the torsed appendage as a lesion of low echogenicity with a central hypoechoic area [35]. Color Doppler imaging reveals normal blood flow to the testis with an occasional increase on the affected side, possibly related to inflammation.

Management of acute torsion of the appendix testis consists of the local application of ice and nonsteroidal antiinflammatory drugs (NSAIDs). Recovery is gradual, with some discomfort often lasting for weeks to months. Surgical excision of the appendix testis is reserved for patients who have persistent pain in spite of these measures.

- **Trauma** – It is common for men to suffer minor scrotal trauma with daily activities. However, only rarely does it result in severe testicular injury, usually from compression of the testis against the pubic bones from a direct blow or straddle injury. The spectrum of traumatic complications can range from a hematocele (blood within the tunica vaginalis) to a pyocele (pus within the tunica vaginalis) to testicular rupture. Color Doppler ultrasonography can accurately diagnose the extent of any injury. Testicular rupture requires surgical repair. Uncomplicated injuries are managed conservatively. Young men who engage in sports where blunt scrotal injury risk is high (eg, hockey, lacrosse) should wear appropriate protection.
- **Post-vasectomy pain** – Patients who have had a vasectomy may have firmness in the entire epididymis secondary to ductal obstruction. Some men will develop a painful nodule at the site of division of the vas deferens on the testicular side. The nodule is a sperm granuloma that forms because of leakage of sperm from the lumen of the vas deferens, creating an immunologic response to the "foreign" protein, which was previously sequestered from immune surveillance by the blood-testis barrier. Management consist of NSAIDs, local application of ice (10 to 15 minutes a few times/day) for one to two days, and warm baths (20 minutes daily) thereafter. Rarely, patients who have intractable pain may require surgical excision of the granuloma.

- **Inguinal hernia** – Herniation of bowel or omentum through the inguinal canal into the scrotum can present with pain and a scrotal mass. Examination for an inguinal hernia is best performed with the patient standing. The inguinal areas should be inspected for bulges, and a provocative maneuver (eg, cough) may be necessary to expose the hernia. If a hernia is not apparent on inspection, the cough should be repeated as the clinician invaginates the upper scrotum. A strangulated hernia may be associated with severe pain ( [picture 3](#)). Pain with inguinal hernias is most likely to be localized in the groin or abdomen rather than the scrotum. Bowel sounds may be audible in the scrotum. Groin ultrasound or CT scan may be helpful if the clinical diagnosis is uncertain. Management of inguinal hernias is discussed separately. (See "[Classification, clinical features, and diagnosis of inguinal and femoral hernias in adults](#)" and "[Overview of treatment for inguinal and femoral hernia in adults](#)".)
- **Mumps orchitis** – Mumps is an acute self-limited viral syndrome characterized by malaise, headache, myalgias, anorexia, and parotid swelling. Epididymo-orchitis is the most common complication of mumps in the adult male, with most patients having fever and parotitis preceding the onset of orchitis. There is often severe testicular pain and tenderness, with swelling and erythema of the scrotum ( [picture 4](#)); bilateral involvement is present in up to 30 percent of cases. Diagnosis is suspected clinically but can be confirmed serologically. Patients with mumps orchitis are managed symptomatically with the local application of ice, scrotal elevation, and NSAIDs. (See "[Mumps](#)", section on 'Orchitis or oophoritis'.)
- **Testicular cancer** – While most testicular tumors present as painless nodules, rapidly growing germ cell tumors may cause acute scrotal pain secondary to hemorrhage and infarction. A mass is generally palpable, and scrotal ultrasound should be performed to confirm the diagnosis. (See "[Clinical manifestations, diagnosis, and staging of testicular germ cell tumors](#)", section on 'Clinical manifestations'.)
- **Immunoglobulin A vasculitis (Henoch-Schönlein purpura)** – Immunoglobulin A (IgA) vasculitis is a systemic vasculitis characterized by nonthrombocytopenic purpura, arthralgia, renal disease, abdominal pain, gastrointestinal bleeding, and occasionally scrotal pain. Scrotal pain can be the presenting symptom, and its onset may be acute or insidious. The diagnosis is often suspected clinically, but scrotal ultrasound may need to be performed to distinguish IgA vasculitis from testicular torsion. It generally shows marked edema of the scrotal skin and contents with intact vascular flow in the testes. Management of scrotal pain is symptomatic. (See "[IgA vasculitis \(Henoch-Schönlein purpura\): Clinical manifestations and diagnosis](#)" and "[IgA vasculitis \(Henoch-Schönlein purpura\): Management](#)".)

- **Acute idiopathic scrotal edema** – Some men develop significant scrotal or penile edema of unknown etiology, usually without pain [36,37]. The condition has been more often reported in children [37]. It should be differentiated from anasarca (generalized edema), in which excess extracellular fluid can collect in the loose scrotal sac. (See ["Clinical manifestations and evaluation of edema in adults"](#).)

In men with acute idiopathic scrotal edema, ultrasonography should be performed to assess for testicular abnormalities. It typically shows thickening of the subcutaneous scrotal tissue without other lesions or masses [36]. Management consists of scrotal elevation, and the condition generally resolves within 48 hours [36].

- **Referred pain** – Men who have the acute onset of scrotal pain without tenderness, swelling, or other findings on physical examination may have referred pain to the scrotum. The conditions that cause referred pain are diverse, reflecting the anatomy of the somatic nerves (genitofemoral, ilioinguinal, and posterior scrotal) that travel to the scrotum [38]. They include abdominal aortic aneurysm, urolithiasis, lower lumbar or sacral nerve root impingement, retrocecal appendicitis, retroperitoneal tumor, and post-herniorrhaphy state.

---

## INFORMATION FOR PATIENTS

UpToDate offers two types of patient education materials, "The Basics" and "Beyond the Basics." The Basics patient education pieces are written in plain language, at the 5<sup>th</sup> to 6<sup>th</sup> grade reading level, and they answer the four or five key questions a patient might have about a given condition. These articles are best for patients who want a general overview and who prefer short, easy-to-read materials. Beyond the Basics patient education pieces are longer, more sophisticated, and more detailed. These articles are written at the 10<sup>th</sup> to 12<sup>th</sup> grade reading level and are best for patients who want in-depth information and are comfortable with some medical jargon.

Here are the patient education articles that are relevant to this topic. We encourage you to print or e-mail these topics to your patients. (You can also locate patient education articles on a variety of subjects by searching on "patient info" and the keyword(s) of interest.)

- Basics topics (see ["Patient education: Epididymitis \(The Basics\)"](#))

---

## SUMMARY AND RECOMMENDATIONS

- The acute scrotum is defined as moderate to severe scrotal pain that develops over the course of minutes to one to two days. (See ["Introduction"](#) above.)

- The most common causes of acute scrotal pain in adults are acute epididymitis and testicular torsion. Other conditions that may be responsible include Fournier's gangrene (necrotizing fasciitis of the perineum), torsion of the appendix testis, trauma, post-vasectomy pain, inguinal hernia, mumps orchitis, testicular cancer, immunoglobulin A (IgA) vasculitis (Henoch-Schönlein purpura), referred pain, and acute idiopathic scrotal edema. (See ['Acute epididymitis or epididymo-orchitis'](#) above and ['Testicular torsion'](#) above and ['Fournier's gangrene'](#) above and ['Other etiologies'](#) above.)
- The first priority in the evaluation of the acute scrotum is to identify any condition that requires urgent medical or surgical intervention. Delayed diagnosis and treatment of acute epididymitis is associated with increased morbidity. Delayed surgical intervention of testicular torsion can lead to loss of the testis, infertility, and other complications. Although much less common, Fournier's gangrene (necrotizing fasciitis of the perineum), which can cause acute scrotal swelling, is a surgical emergency. (See ['Conditions requiring emergent treatment'](#) above.)
- The initial evaluation of acute scrotal pain includes a directed history and physical examination. Patients should be asked about the nature and timing of the onset of pain, its location, and the presence of lower urinary tract symptoms (eg, frequency, urgency, dysuria) and constitutional symptoms (eg, fever, chills). The abdomen, inguinal region, and scrotal skin and contents should be carefully examined ( [figure 1](#)). A urinalysis and urine culture, as well as diagnostic studies for *Neisseria gonorrhoeae* and *Chlamydia trachomatis* should be obtained if the diagnosis of acute epididymitis is being considered or if lower urinary tract symptoms are present. A diagnostic approach based upon characteristic clinical features can be used for evaluation of the acute scrotum ( [table 1](#)). (See ['Initial evaluation'](#) above.)
- The clinical features of acute epididymitis include localized testicular pain with tenderness and swelling on palpation of the affected epididymis, which is located posteriorly on the testis ( [figure 1](#)). The diagnosis is made presumptively based on history and physical examination after ruling out other causes requiring urgent intervention. Identification of a pathogen on urine or urethral swab testing supports the presumptive diagnosis. (See ['Acute epididymitis or epididymo-orchitis'](#) above.)
- Empiric antimicrobial treatment for acute epididymitis should be given pending nucleic acid amplification test (NAAT) and culture results based on the most likely pathogens as follows (see ['Management'](#) above):
  - In patients under the age of 35 or who are at risk of sexually transmitted infections, we suggest coverage for *N. gonorrhoeae* and *C. trachomatis* (**Grade 2C**). [Ceftriaxone](#) (500 mg intramuscular injection in one dose, or 1 g if patient weighs 150 kg or greater) **plus** [doxycycline](#) (100 mg orally twice a day for 10 days) is an acceptable

regimen. [Azithromycin](#) (1 g orally in one dose) is an alternative option in patients unable to tolerate doxycycline. Fluoroquinolones are not recommended for the treatment of acute epididymitis if gonorrhea is suspected because of the widespread resistance of *N. gonorrhoeae* to these drugs.

- In patients 35 years of age or older who are at low risk for sexually transmitted infections, we suggest coverage for enteric pathogens (**Grade 2C**). [Levofloxacin](#) 500 mg orally once daily for 10 days is an acceptable regimen. For patients who are unable to take fluoroquinolones, [trimethoprim-sulfamethoxazole](#) (one double-strength tablet twice a day for 10 days) is a good alternative.
- In patients of any age who practice insertive anal intercourse, we suggest coverage for *N. gonorrhoeae*, *C. trachomatis*, and enteric pathogen infections (**Grade 2C**). [Ceftriaxone](#) (500 mg intramuscular injection in one dose, or 1 g if patient weighs 150 kg or greater) **plus** [levofloxacin](#) 500 mg orally once daily for 10 days is an acceptable regimen.
- The clinical features of testicular torsion include the acute onset of moderate to severe testicular pain with profound diffuse tenderness and swelling and a negative cremasteric reflex on physical examination. Doppler ultrasound of the scrotum is a useful adjunct in equivocal cases but should not delay surgical exploration. Urgent surgical exploration is the standard of care for testicular torsion. For patients who cannot be taken to surgery within two hours, an attempt at manual detorsion is warranted ( [figure 5](#)). Surgical exploration is necessary even after successful manual detorsion because orchiopexy (securing the testicle to the scrotal wall) must be performed to prevent recurrence, and residual torsion may be present that can be further relieved. (See '[Testicular torsion](#)' above.)
- Fournier's gangrene is a necrotizing fasciitis (mixed aerobic/anaerobic infection) of the perineum which often involves the scrotum. It is characterized by severe pain that generally starts on the anterior abdominal wall and migrates into the gluteal muscles, scrotum, and penis ( [picture 1](#)). Clinical features may include tense edema outside the involved skin, blisters/bullae, crepitus, and subcutaneous gas, as well as systemic findings such as fever, tachycardia, and hypotension. Management of necrotizing fasciitis consists of early aggressive surgical debridement, broad spectrum antibiotic therapy, and hemodynamic support as needed. (See "[Necrotizing soft tissue infections](#)" and '[Fournier's gangrene](#)' above.)

Use of UpToDate is subject to the [Subscription and License Agreement](#).

## REFERENCES



1. [Rabinowitz R. The importance of the cremasteric reflex in acute scrotal swelling in children. J Urol 1984; 132:89.](#)
2. [Trojian TH, Lishnak TS, Heiman D. Epididymitis and orchitis: an overview. Am Fam Physician 2009; 79:583.](#)
3. [Stewart A, Ubee SS, Davies H. Epididymo-orchitis. BMJ 2011; 342:d1543.](#)
4. [Tracy CR, Steers WD, Costabile R. Diagnosis and management of epididymitis. Urol Clin North Am 2008; 35:101.](#)
5. [Doble A, Taylor-Robinson D, Thomas BJ, et al. Acute epididymitis: a microbiological and ultrasonographic study. Br J Urol 1989; 63:90.](#)
6. [Hawkins DA, Taylor-Robinson D, Thomas BJ, Harris JR. Microbiological survey of acute epididymitis. Genitourin Med 1986; 62:342.](#)
7. [Wampler SM, Llanes M. Common scrotal and testicular problems. Prim Care 2010; 37:613.](#)
8. [https://www.cdc.gov/mmwr/volumes/69/wr/mm6950a6.htm?s\\_cid=mm6950a6\\_e&ACSTrackingID=USCDC\\_921-DM44810&ACSTrackingLabel=This%20Week%20in%20MMWR%20-%20Vol.%2069%2C](https://www.cdc.gov/mmwr/volumes/69/wr/mm6950a6.htm?s_cid=mm6950a6_e&ACSTrackingID=USCDC_921-DM44810&ACSTrackingLabel=This%20Week%20in%20MMWR%20-%20Vol.%2069%2C) (Accessed on January 14, 2021).
9. [Molokwu CN, Somani BK, Goodman CM. Outcomes of scrotal exploration for acute scrotal pain suspicious of testicular torsion: a consecutive case series of 173 patients. BJU Int 2011; 107:990.](#)
10. [Cummings JM, Boullier JA, Sekhon D, Bose K. Adult testicular torsion. J Urol 2002; 167:2109.](#)
11. [al Mufti RA, Ogedegbe AK, Lafferty K. The use of Doppler ultrasound in the clinical management of acute testicular pain. Br J Urol 1995; 76:625.](#)
12. [Watkin NA, Reiger NA, Moisey CU. Is the conservative management of the acute scrotum justified on clinical grounds? Br J Urol 1996; 78:623.](#)
13. [Tajchner L, Larkin JO, Bourke MG, et al. Management of the acute scrotum in a district general hospital: 10-year experience. ScientificWorldJournal 2009; 9:281.](#)
14. [Hegarty PK, Walsh E, Corcoran MO. Exploration of the acute scrotum: a retrospective analysis of 100 consecutive cases. Ir J Med Sci 2001; 170:181.](#)
15. [Dunne PJ, O'Loughlin BS. Testicular torsion: time is the enemy. Aust N Z J Surg 2000; 70:441.](#)
16. [Jarow JP, Sanzone JJ. Risk factors for male partner antisperm antibodies. J Urol 1992; 148:1805.](#)
17. [DaJusta DG, Granberg CF, Villanueva C, Baker LA. Contemporary review of testicular torsion: new concepts, emerging technologies and potential therapeutics. J Pediatr Urol 2013; 9:723.](#)

18. [Schmitz D, Safranek S. Clinical inquiries. How useful is a physical exam in diagnosing testicular torsion? J Fam Pract 2009; 58:433.](#)
19. [Liguori G, Bucci S, Zordani A, et al. Role of US in acute scrotal pain. World J Urol 2011; 29:639.](#)
20. [Wilbert DM, Schaerfe CW, Stern WD, et al. Evaluation of the acute scrotum by color-coded Doppler ultrasonography. J Urol 1993; 149:1475.](#)
21. [Kapasi Z, Halliday S. Best evidence topic report. Ultrasound in the diagnosis of testicular torsion. Emerg Med J 2005; 22:559.](#)
22. [Pepe P, Panella P, Pennisi M, Aragona F. Does color Doppler sonography improve the clinical assessment of patients with acute scrotum? Eur J Radiol 2006; 60:120.](#)
23. [Kalfa N, Veyrac C, Baud C, et al. Ultrasonography of the spermatic cord in children with testicular torsion: impact on the surgical strategy. J Urol 2004; 172:1692.](#)
24. [Vijayaraghavan SB. Sonographic differential diagnosis of acute scrotum: real-time whirlpool sign, a key sign of torsion. J Ultrasound Med 2006; 25:563.](#)
25. [Kalfa N, Veyrac C, Lopez M, et al. Multicenter assessment of ultrasound of the spermatic cord in children with acute scrotum. J Urol 2007; 177:297.](#)
26. [Kutikov A, Casale P, White MA, et al. Testicular compartment syndrome: a new approach to conceptualizing and managing testicular torsion. Urology 2008; 72:786.](#)
27. [Kaye JD, Shapiro EY, Levitt SB, et al. Parenchymal echo texture predicts testicular salvage after torsion: potential impact on the need for emergent exploration. J Urol 2008; 180:1733.](#)
28. [Sessions AE, Rabinowitz R, Hulbert WC, et al. Testicular torsion: direction, degree, duration and disinformation. J Urol 2003; 169:663.](#)
29. Perron CE. Pain: Scrotal. In: Textbook of Pediatric Emergency Medicine, 4th ed, Fleisher GR, Ludwig S (Eds), Lippincott, Williams & Wilkins, Philadelphia 2000. p.473.
30. [Voelzke BB, Hagedorn JC. Presentation and Diagnosis of Fournier Gangrene. Urology 2018; 114:8.](#)
31. [Palestro CJ, Manor EP, Kim CK, Goldsmith SJ. Torsion of a testicular appendage in an adult male. Clin Nucl Med 1990; 15:515.](#)
32. [Fisher R, Walker J. The acute paediatric scrotum. Br J Hosp Med 1994; 51:290.](#)
33. [Ringdahl E, Teague L. Testicular torsion. Am Fam Physician 2006; 74:1739.](#)
34. [Kadish HA, Bolte RG. A retrospective review of pediatric patients with epididymitis, testicular torsion, and torsion of testicular appendages. Pediatrics 1998; 102:73.](#)
35. [Hesser U, Rosenborg M, Gierup J, et al. Gray-scale sonography in torsion of the testicular appendages. Pediatr Radiol 1993; 23:529.](#)

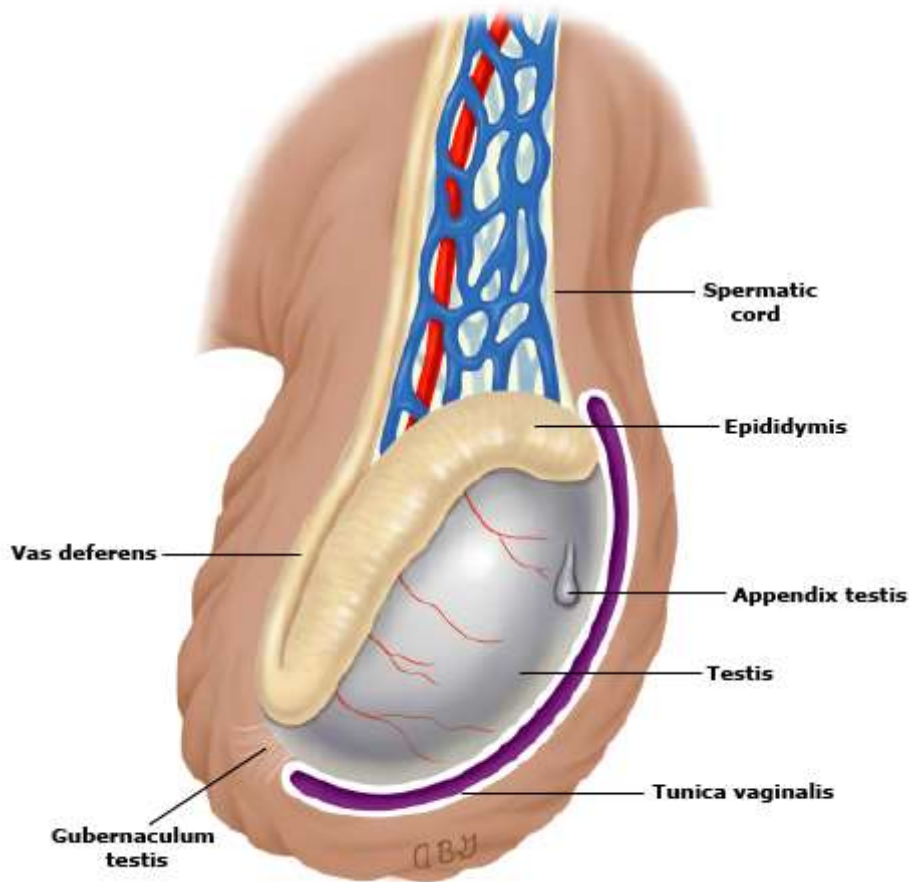
36. [Shah J, Qureshi I, Ellis BW. Acute idiopathic scrotal oedema in an adult: a case report. Int J Clin Pract 2004; 58:1168.](#)
37. [Ooi DG, Chua MT, Tan LG. A case of adult acute idiopathic scrotal edema. Nat Rev Urol 2009; 6:331.](#)
38. [McGee SR. Referred scrotal pain: case reports and review. J Gen Intern Med 1993; 8:694.](#)

Topic 6873 Version 49.0

## GRAPHICS

### Normal testicular anatomy

---



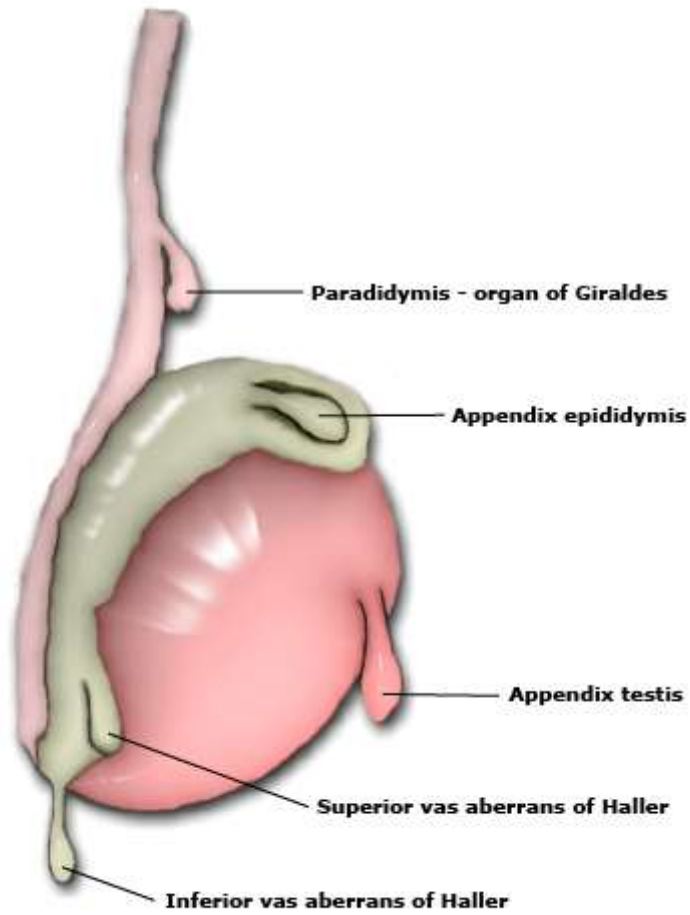
---

The testicle is vertical and its anterior portion is surrounded by the tunica vaginalis.

Graphic 75672 Version 3.0

## Anatomy of the testicular appendages

---



Graphic 67439 Version 3.0

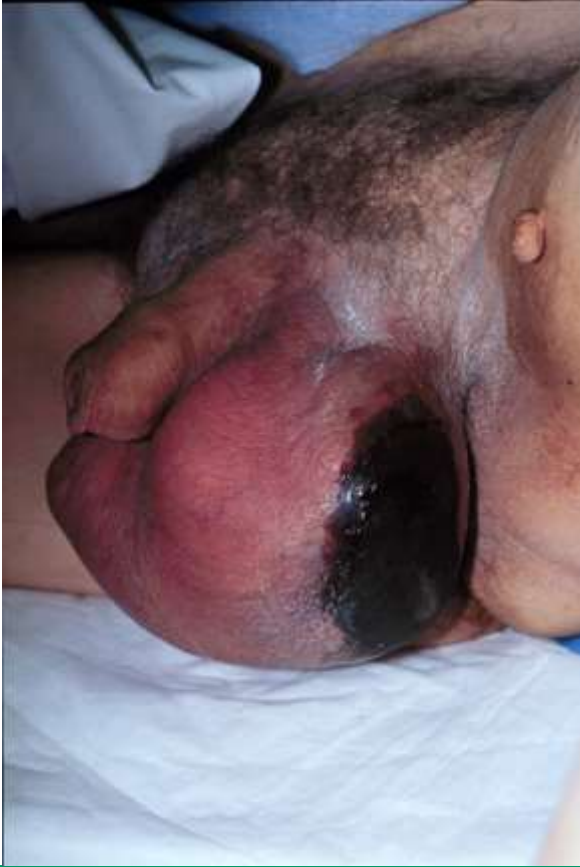### Distinguishing conditions responsible for acute scrotal pain in adults

	Symptom onset	Pain location	Cremasteric reflex	Other clinical findings
Appendiceal torsion	Acute or subacute	Upper pole of testis	Positive	Blue dot sign
Epididymitis	Acute or chronic	Epididymis	Positive	Positive urinalysis, urine culture, or diagnostic tests for gonorrhea or <i>Chlamydia</i> infection
Fournier's gangrene	Acute	Diffuse	Positive	Tense edema outside of involved skin, blisters/bullae, crepitus, fever, rigors, hypotension
Testicular torsion	Acute	Testis	Negative	High-riding testis, bell clapper deformity, profound testicular swelling

Graphic 56026 Version 6.0

## Fournier's gangrene in a patient with diabetes

---



---

Necrotizing fasciitis of the perineum (Fournier's gangrene) can involve the scrotum. The infection can begin abruptly with severe pain and may spread rapidly.

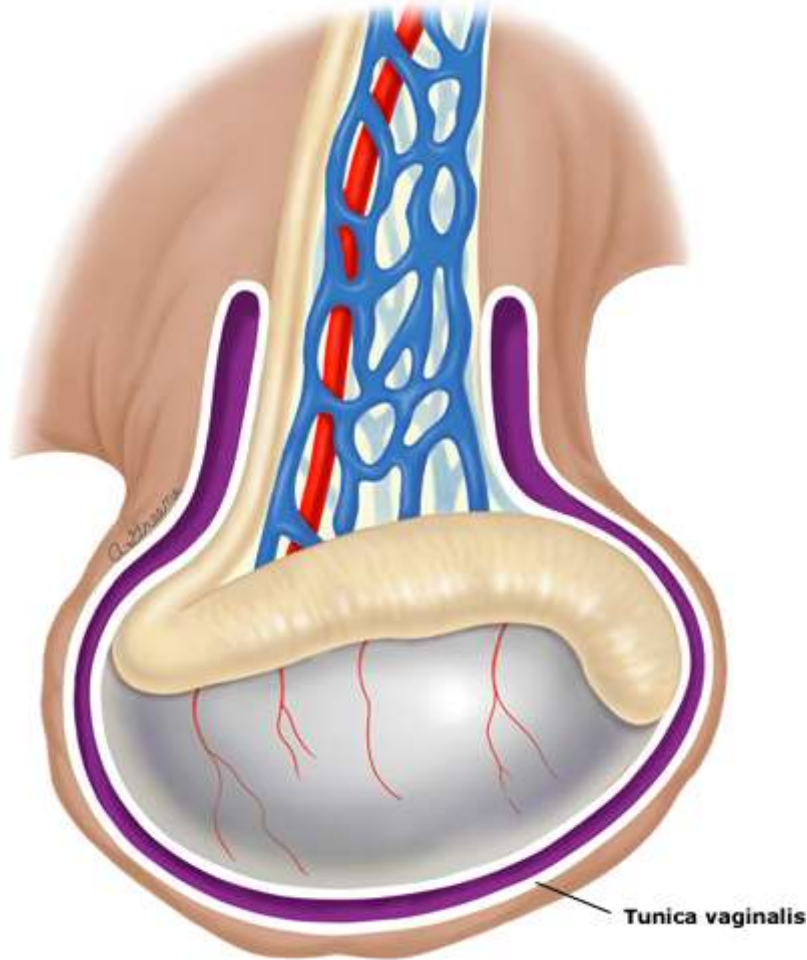
---

*Reproduced with permission from Lawrence B Stack, MD.*

Graphic 58093 Version 1.0

## Bell clapper deformity

---



---

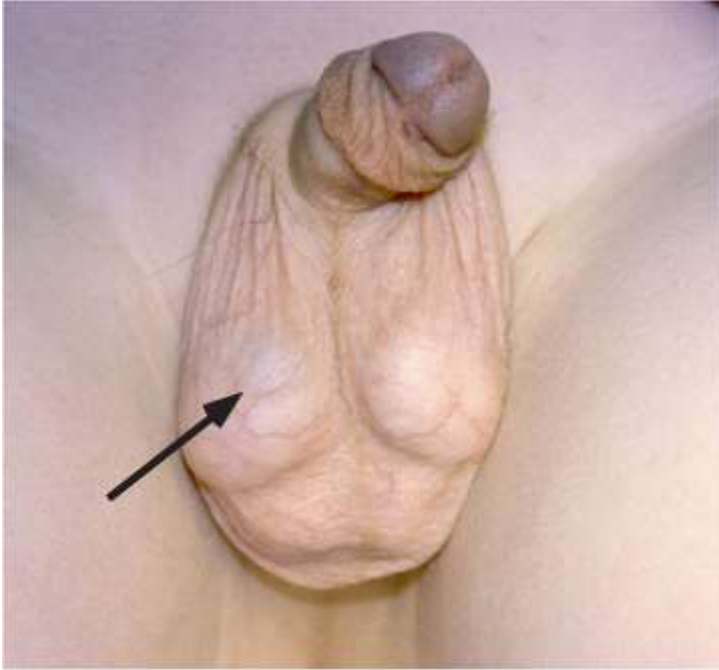In the "bell clapper" deformity, the testis lies horizontally and the tunica vaginalis extends up over the spermatic cord so that the testis is suspended within the tunica vaginalis by the spermatic cord.

Graphic 55518 Version 4.0



## Torsion of the appendix testis

---



---

The appendix testis is a 0.3 cm pedunculated structure on the anterosuperior aspect of the testis. Torsion can produce testicular pain that ranges from mild to severe. Infarction and necrosis of the appendix testis can be seen as a "blue dot" sign (arrow) in 21% of cases.

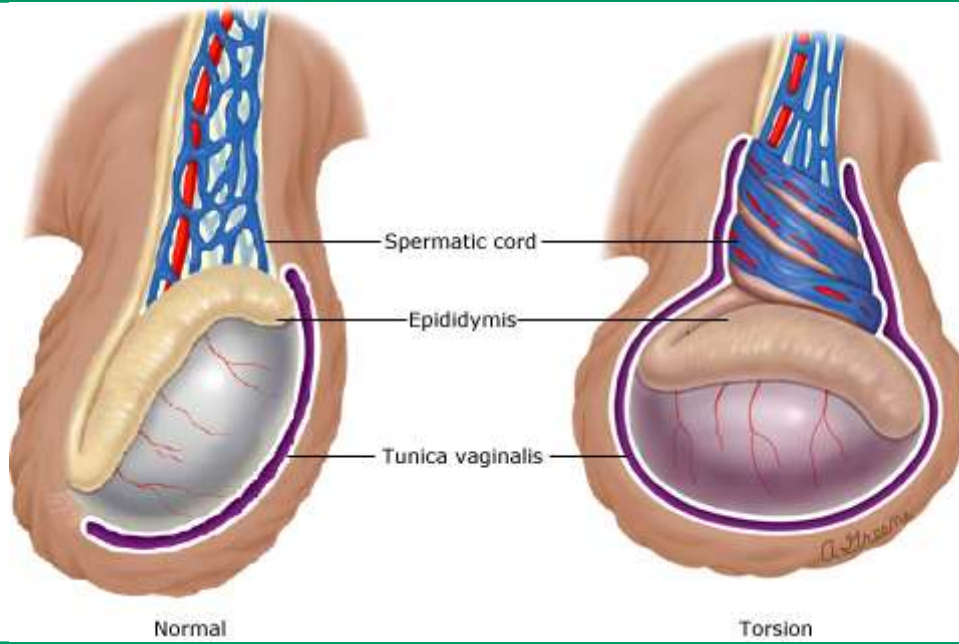
---

*Reproduced with permission from Charise Johns, MD.*

Graphic 65781 Version 3.0

## Torsion of spermatic cord

---

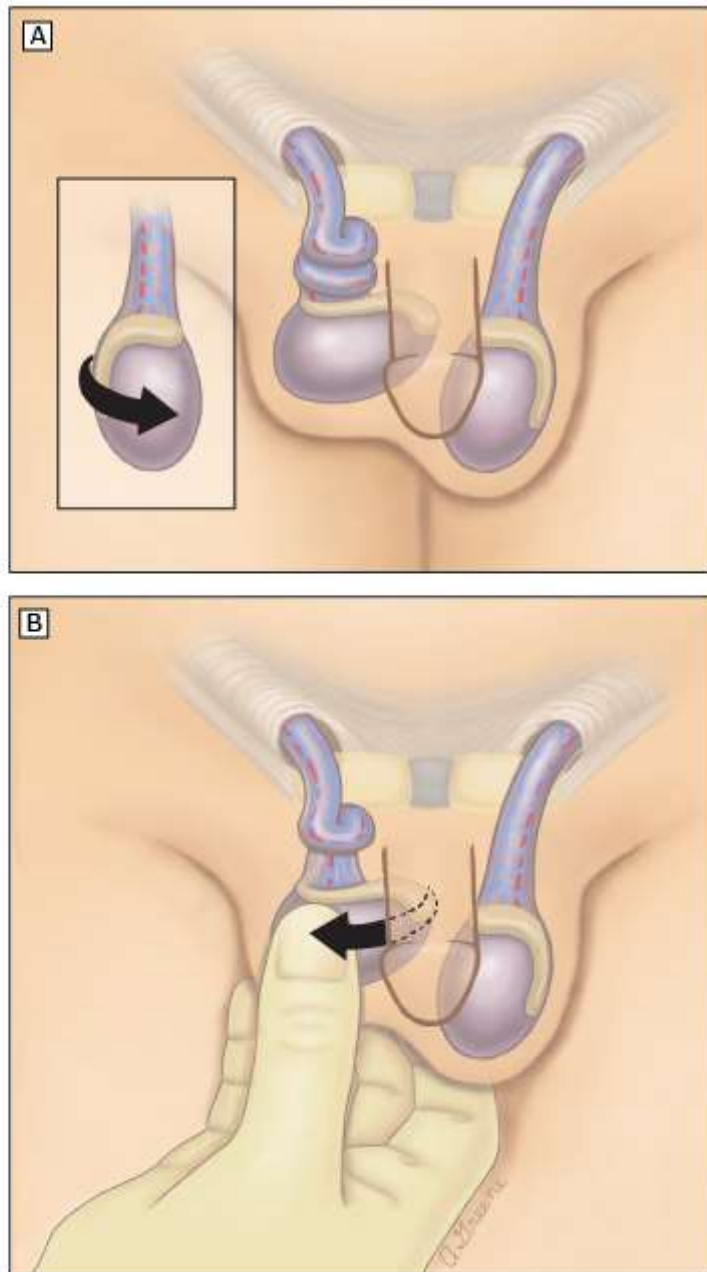


---

Abnormality of testicular fixation permits torsion of spermatic vessels with subsequent infarction of the gonad.

Graphic 77468 Version 2.0

## Manual detorsion of the testicle



(A) The right testicle shows the characteristic medial torsion with elevation and horizontal lie of the testis.

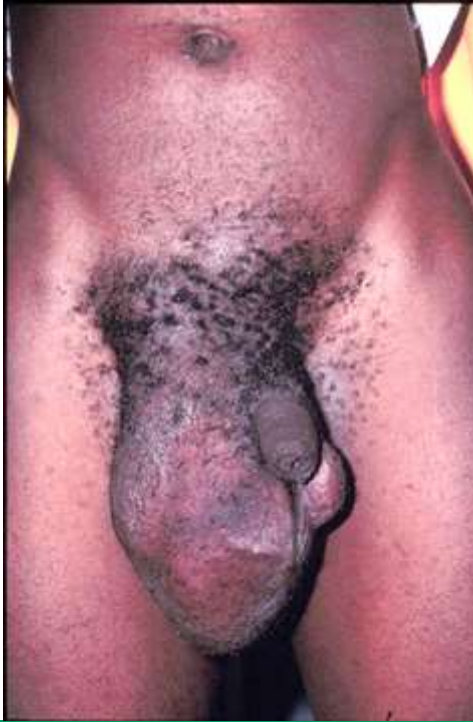(B) After appropriate sedation and analgesia has been administered, manual detorsion is performed by grasping the testicle and rotating it within the scrotum outward (medial to lateral) one to two full 360 degree turns. Prompt relief of pain, lower position of the testis in the scrotum, and return of arterial flow on Doppler ultrasound suggests detorsion. If there is no improvement, try rotating the testicle in the opposite direction (lateral to medial) because approximately one-third of torsed testicles may have lateral rotation.

*Modified from: Cronan KM, Zderic SA. Manual detorsion of the testes. In: Textbook of Pediatric Emergency Procedures, 2nd ed, King C, Henretig FM (Eds), Lippincott Williams & Wilkins, Philadelphia 2008.*

Graphic 112358 Version 2.0

## Strangulated hernia

---



---

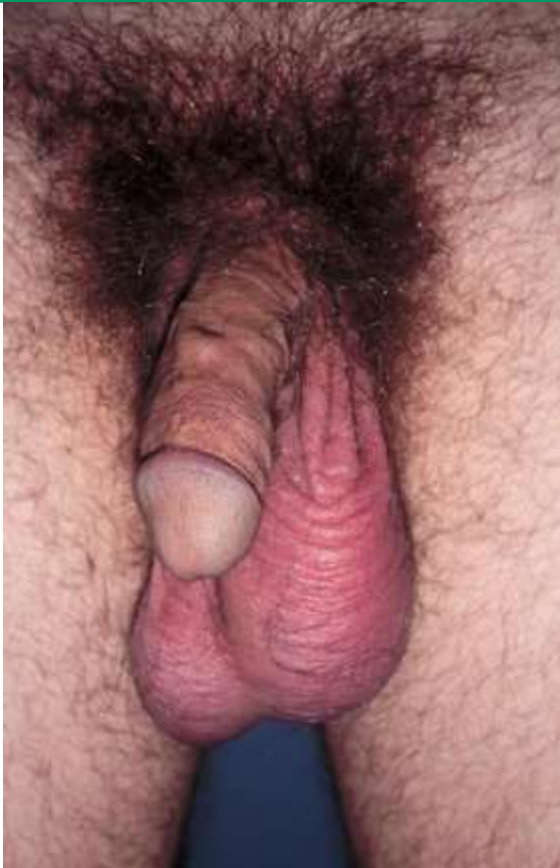Scrotal swelling is seen in a patient with a strangulated indirect inguinal hernia.

*Reproduced with permission from Lawrence B Stack, MD.*

Graphic 76424 Version 1.0

## Mumps orchitis

---



---

Epididymo-orchitis is the most common complication of mumps infection in the adult male. It is frequently characterized by the abrupt onset of fever from 39 to 41°C and severe testicular pain, accompanied by swelling and erythema of the scrotum.

*Reproduced with permission from Lawrence B Stack, MD.*

Graphic 66233 Version 1.0

## Contributor Disclosures

**Robert C Eyre, MD** Nothing to disclose **Michael P O'Leary, MD, MPH** Nothing to disclose **Jane Givens, MD** Nothing to disclose

Contributor disclosures are reviewed for conflicts of interest by the editorial group. When found, these are addressed by vetting through a multi-level review process, and through requirements for references to be provided to support the content. Appropriately referenced content is required of all authors and must conform to UpToDate standards of evidence.

[Conflict of interest policy](#)

→